



NATIONAL RESEARCH UNIVERSITY
HIGHER SCHOOL OF ECONOMICS

*Roza M. Vlasova, Ekaterina V. Pechenkova,
Valentin E. Sinitsyn*

fMRI CORRELATES OF THE WORD FREQUENCY EFFECT IN RUSSIAN

BASIC RESEARCH PROGRAM

WORKING PAPERS

SERIES: LINGUISTICS
WP BRP 02/LNG/2013

Roza M. Vlasova¹, Ekaterina V. Pechenkova², Valentin E. Sinitsyn³

fMRI CORRELATES OF THE WORD FREQUENCY EFFECT IN RUSSIAN

Abstract

The results of the previous fMRI study of the word frequency effect in Russian (Malutina et al., 2012) contradict the results obtained from fMRI studies of English speakers. Two reasons for such inconsistency may be either task specificity (tasks involving verbs vs. tasks involving nouns) or cross-linguistic differences. This study examines fMRI correlates of word frequency in Russian using an object naming task. We found that several brain regions were more activated by the retrieval of low frequency rather than high frequency words: the fusiform gyrus, the inferior occipital gyrus, the middle occipital gyrus, the supplementary motor area, the inferior frontal gyrus bilaterally, the left thalamus, the left insula, and the right cingulate gyrus. At the same time we revealed no brain areas responding more to high frequency words. These results are consistent with the previous fMRI studies in English and also indicate the possible role of task specificity as well as possible interactions of task and word frequency in brain mechanisms for word retrieval.

Keywords: word frequency effect, object naming, fMRI (functional magnetic resonance imaging), Russian language.

JEL Classification: Z19.

¹ Higher School of Economics, Faculty of Philology, Laboratory of Neurolinguistics

² Institute of Practical Psychology and Psychoanalysis

³ Federal Center of Medicine and Rehabilitation

Introduction

One of the main linguistic characteristics of an individual word is word frequency, or how often this word appears in the language. The effect of word frequency on response time has been shown in many behavioral studies using object naming, lexical decision and reading tasks indicating that low frequency words are processed slower than high frequency words. This phenomenon is called “the word frequency effect” (Liu et al., 2004; Meschyan, Hernandez, 2002; Jescheniak & Levelt, 1994; Gardner et al., 1987; Oldfield & Wingfield, 1965). fMRI studies of the neural substrate of this effect are not numerous because word frequency correlates with a number of lexical dimensions such as phoneme and grapheme distribution, so that neurolinguistic research on the word frequency effect per se requires disentangling these variables which is very difficult (Gardner et al, 1987). However, several papers reported that compared to high frequency words, low frequency words elicited greater activation in the superior frontal gyrus, the pars opercularis and the pars triangularis of the left inferior frontal gyrus, the anterior insula, the thalamus and the caudate nucleus (Fiebach et al., 2002; Chee et al., 2003), the left superior temporal gyrus and the temporo-occipital region (Graves et al., 2007). At the same time, no brain areas show greater activation for high frequency word retrieval (Graves et al., 2007; Fiebach et al., 2002; Chee et al., 2003). Such outcomes can be easily predicted if task difficulty is taken into account, since in fMRI research greater brain activation is coupled with higher mental effort (Liu et al., 2004; Khushu et al., 2001), and word perception or production is more difficult for low frequency words.

There are few fMRI studies of speech processing in Russian language. One of these studies used verb retrieval in a picture naming task and shows specific brain activation for both low frequency and high frequency verbs (Malutina et al., 2012). According to this paper, the retrieval of high frequency verbs in a picture naming task was associated with bilateral activation in the occipital areas (BA 18, 19), the superior parietal gyrus (BA 7), the right orbitofrontal area (BA 10, 11), the right precuneus (BA 7), the right cuneus (BA 17), the right middle temporal gyrus (BA 39), the left calcarine sulcus (BA 30), the left lingual gyrus (BA 30). The retrieval of low frequency verbs was associated with increased activation in the superior frontal gyrus (BA 6, 8), the supplementary motor area (BA 6), the medial frontal gyrus (BA 6, 8, 9), the left and right cingulate gyrus (BA 24, 32), the right sensorimotor cortex (BA 1, 3, 4), the right middle and inferior frontal gyrus (BA 6, 8, 9, 10) and the right superior temporal gyrus (BA 42) (Malutina et al., 2012).

These results contradict previous data obtained in fMRI studies of English speakers. Two reasons for such inconsistency may be either the task specificity or cross-linguistic differences.

The morphology of Russian is different from that of English. However, an explanation in terms of cross-linguistic differences does not seem plausible because brain correlates of the word frequency effect very similar to those obtained for English were also found in languages that are even less similar to English than Russian, for example, Chinese (Lee et al., 2003). At the same time the observed inconsistency may be due to difference in neural substrate for retrieval of nouns and verbs, since Malyutina et al. (2012) used action naming which is a verb-retrieval task, while the majority of previous fMRI research on the word frequency effect has been conducted using noun-retrieval tasks such as object naming, reading, and lexical decision. Therefore the aim of the present study was to replicate in Russian the previous results on neural correlates of the word frequency effect found in other languages. Taking into account possible task specificity, we have chosen an object naming task.

We suppose that several regions associated with word retrieval would demonstrate greater activation for low frequency nouns. At the same time we did not expect any specific activation for high frequency nouns.

Participants

16 healthy right-handed native Russian speakers (9 females; 7 males; mean age 24.3 years (SD=4.17) participated in the study. Informed consent was obtained from all participants in agreement with the Declaration of Helsinki.

Task

A block design with two experimental conditions was used. Conditions were created by manipulating the word frequency rate (low/high): 70 low frequency concrete nouns (mean frequency 4.55 items per million (ipm) and 70 high frequency concrete nouns (mean frequency 116.93 ipm) (Table 1) were selected from “The word frequency vocabulary of modern Russian language” (Lyashevskaya & Sharov, 2009). For each concrete noun we found a realistic pictorial representation of corresponding object (Fig. 1).

Tab. 1. Mean value and standard deviation of stimuli linguistic parameters (for words corresponding to object pictures).

	syllables	frequency (ipm)
high frequency	2.2 (SD=0.7)	116.93 (SD=162.97)
low frequency	2.59 (SD=0.8)	4.55 (SD=2.79)

Participants were asked to silently name the pictures presented on the screen. Each picture was displayed for 3 seconds and there were 7 pictures per block. The same pictures distorted in a way that the objects were no longer identifiable were used as the stimuli for the baseline condition.

The stimulation sequence is depicted in Fig.1.

Method

Structural T1-weighted and functional T2*-weighted volumes (EPI sequence parameters: TR/TE/FA – 2350 ms / 50 ms / 90°; 28 slices oriented parallel to AC/PC plane, interslice interval 0.75 mm; voxel size 3.6x3.6x4 mm) were acquired using Siemens 1.5 T Magnetom Avanto scanner, located at the Federal Center of Medicine and Rehabilitation (Moscow, Russia). 372 functional volumes per subject were collected. Each session lasted for about 15 minutes and included 10 blocks of each of the two experimental conditions alternating with 21 blocks of baseline.

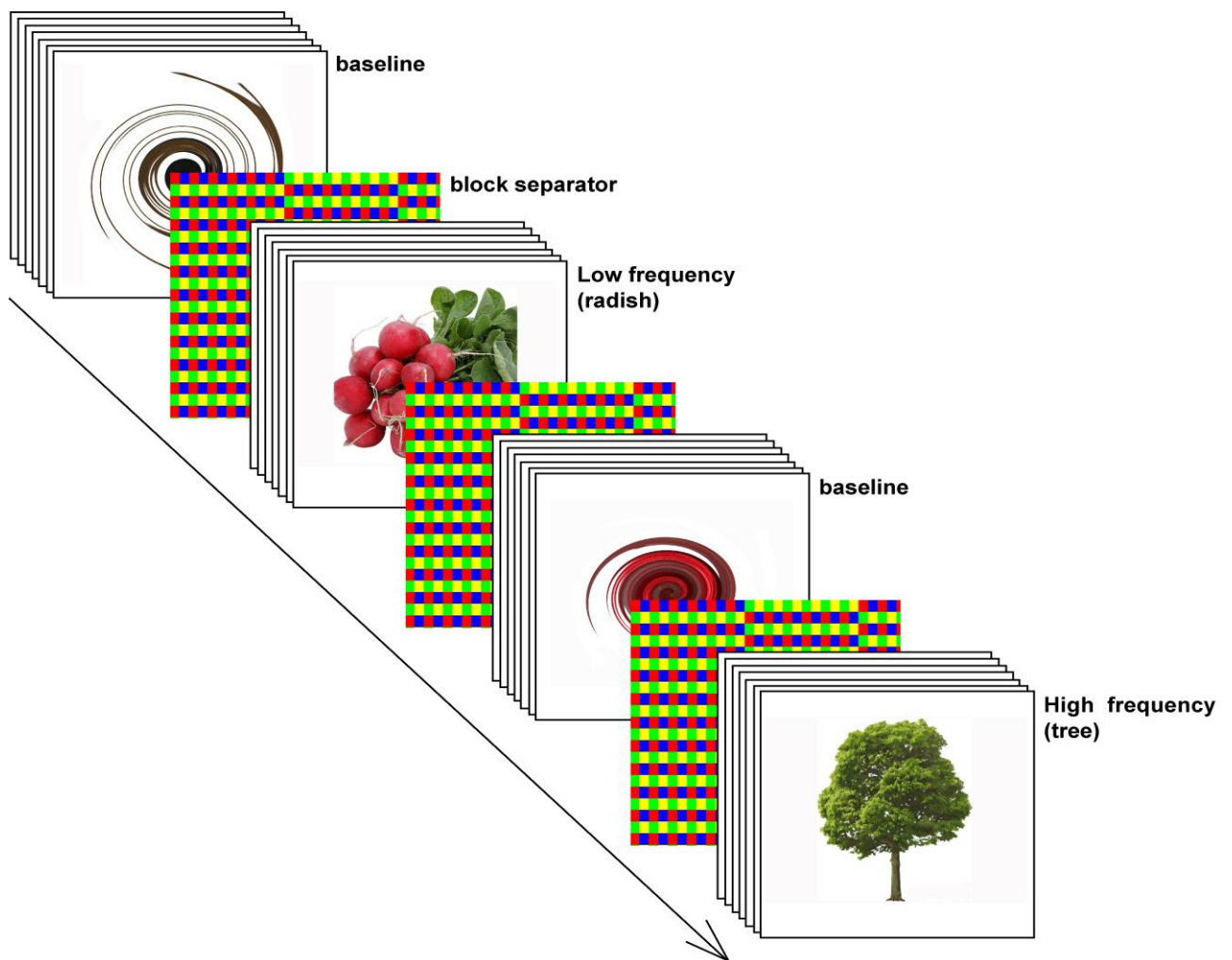


Fig.1. An example of stimulus for the object naming task.

FMRI data analysis

FMRI data were processed using SPM8 software (Wellcome Institute of Cognitive Neurology, www.fil.ion.ucl.ac.uk). The first three volumes of each session were discarded. Data preprocessing included image realignment and unwarping, coregistration of structural and functional images, the segmentation of structural images and spatial normalization to the

standard EPI MNI template for both structural and functional images. For functional images, spatial smoothing with an isotropic 8-mm Gaussian kernel and a temporal high-pass filter (169-second cut off) were also applied. Data for each subject were modeled using the general linear model (Friston et al., 1995). One session, two conditions (low frequency words, high frequency words) were modeled using the canonical hemodynamic response function. T-contrast images from each subject were combined for a group random effect analysis. Peak activation voxels were reported in MNI coordinates.

Results

Bilateral activation peaks were revealed in the fusiform gyrus, the inferior occipital gyrus and the middle occipital gyrus, the supplementary motor area and the inferior frontal gyrus for both low frequency vs. baseline, and high frequency vs. baseline contrasts (Fig. 2 and 3).

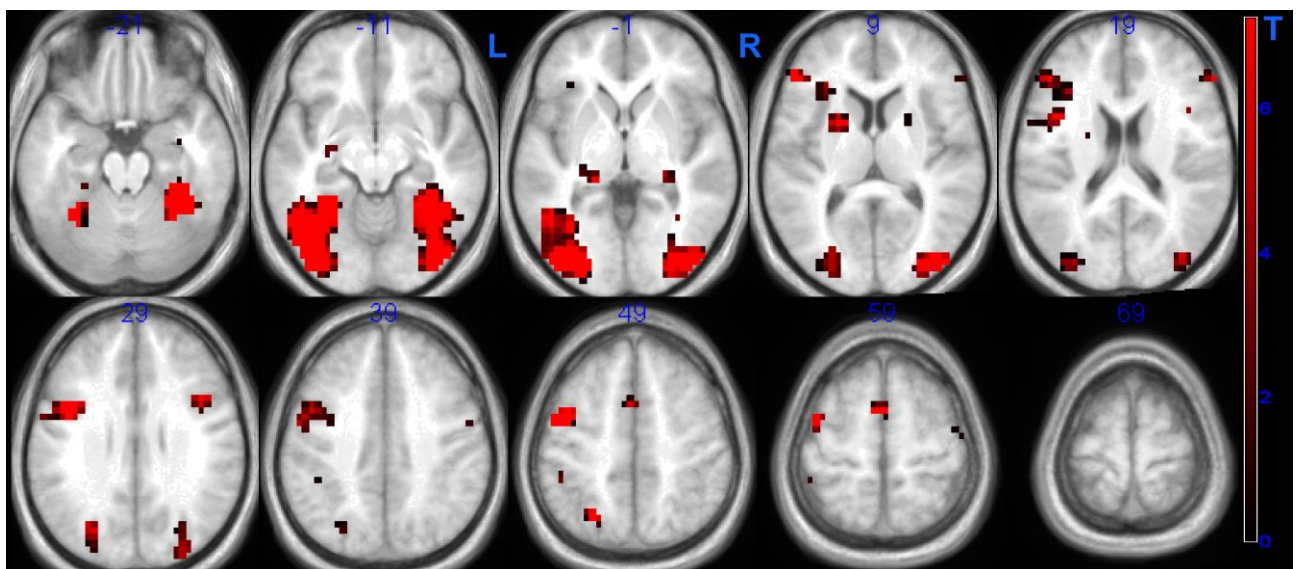


Fig. 2. Clusters of activation for the contrast of high frequency words vs. baseline ($p < 0.05$, FWE corrected, overlayed on averaged group anatomy normalized to MNI space)

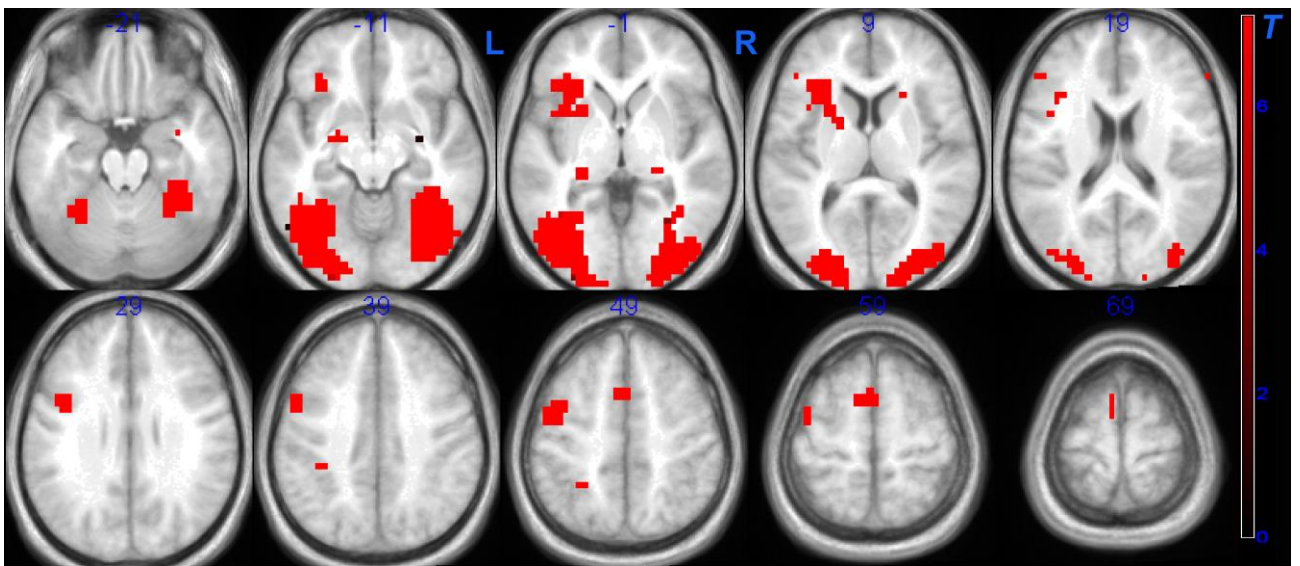


Fig. 3. Clusters of activation for the contrast of low frequency words vs. baseline ($p < 0.05$, FWE corrected, overlaid on averaged group anatomy normalized to MNI space)

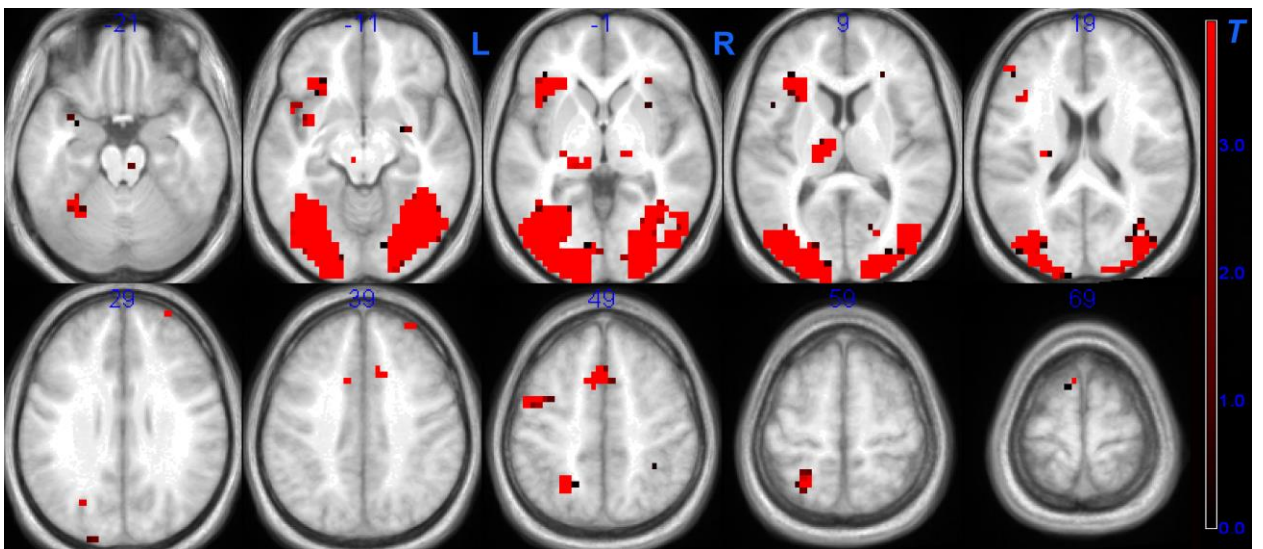


Fig. 4. Clusters of activation for the contrast of low frequency words vs. high frequency words ($p < 0.001$, overlaid on averaged group anatomy normalized to MNI space)

Tab. 2. Number of activated voxels in task-specific regions

	Low frequency vs baseline	High frequency vs baseline
L. Supplementary motor area	44	7
R. Supplementary motor area	7	2
L. Inferior frontal gyrus	48	13
R. Inferior frontal gyrus	5	5
L. Fusiform gyrus, middle occipital gyrus, inferior occipital gyrus	533	491
R. Fusiform gyrus, middle occipital gyrus, inferior occipital gyrus	261	215

Notes: Voxel size=4x4x4 mm (after spatial normalization)

Several brain regions were more activated for the retrieval of low frequency words (Fig. 3). This increase was found bilaterally in the fusiform gyrus, the inferior occipital gyrus, the middle occipital gyrus, the supplementary motor area and the inferior frontal gyrus; also in the left thalamus, the left insula, and the right cingulate gyrus (Tables 2 and 3; Fig.3). We found no brain areas that responded more to high frequency words.

Discussion

We found that the retrieval of low frequency and high frequency words activated the same brain areas (the fusiform gyrus, the inferior occipital gyrus, the middle occipital gyrus, the supplementary motor area and the inferior frontal gyrus bilaterally). These brain regions are traditionally associated with object naming tasks and include the brain areas involved in executive processes (the frontal lobe) as well as areas involved in storage of word representations (the temporal and occipital regions (DeLeon, 2007)).

As expected, we found specificity of activation patterns for low frequency word retrieval and no specific activation for high frequency words. The retrieval of low frequency words results in greater brain activation in task-specific areas and the involvement of additional brain regions (the left thalamus, the left insula and the right cingulate gyrus). Using low frequency words in picture naming requires more effort, so the increasing functional demands may account for the extra activation in task-specific brain areas. This effect is similar to the increase of brain activation that can be seen in the primary motor area as a response to higher tapping rates (Liu et al., 2004; Khushu et al., 2001) or in brain regions associated with speech comprehension as a response to higher syntactic and lexical complexity (Keller et al., 2001).

Tab. 3. Locus and extent of activated clusters

Regions	Cluster level		Voxel level		Coordinates
	Pcorrected	Extent	Pcorrected	t	x y z
low frequency vs baseline (FWE, p=0.05; FDRc=3)					
R. Fusiform gyrus	0.000	491	0.000	18.54	42 -80 2
R. Middle occipital gyrus			0.000	15.53	38 -48 -14
R. Inferior occipital gyrus			0.000	13.94	38 -76 -10
L. Middle occipital gyrus	0.000	533	0.000	15.75	-34 -80 -6
L. Fusiform gyrus			0.000	15.40	-34 -56 -14
L. Inferior occipital gyrus			0.000	15.08	-38 -84 2
L. Supplementary motor area	0.000	51	0.000	10.83	-6 4 62
R. Supplementary motor area			0.004	8.54	-6 12 46
L. Precentral gyrus	0.000	204	0.000	10.76	-46 -4 54
L. Insula			0.000	10.45	-50 -4 46
L. Putamen			0.001	9.73	-22 16 6
R. Hippocampus	0.000	12	0.001	9.68	30 -8 -14
L. Amygdala	0.000	11	0.003	8.76	-22 -8 -10
R. Inferior frontal gyrus, triangular part	0.002	3	0.005	8.40	58 32 14
L. Inferior frontal gyrus	0.000	6	0.008	8.07	-46 32 14
L. Calcarine fissure	0.001	4	0.009	8.01	2 -88 6
L. Hippocampus	0.000	7	0.013	7.79	-26 -32 -2
L. Inferior parietal	0.002	3	0.014	7.74	-30 -52 54
	0.001	4	0.028	7.30	22 -32 2
	0.002	3	0.032	7.22	-38 -36 38
high frequency vs baseline (FWE, p=0.05; FDRc=3)					
L. Fusiform gyrus	0.000	261	0.000	16.35	-50 -56 -10
L. Inferior occipital gyrus			0.000	13.13	-38 -80 -2
L. Middle occipital gyrus			0.000	12.24	-34 -56 -14
R. Fusiform gyrus	0.000	215	0.000	12.78	34 -44 -18
R. Inferior occipital gyrus			0.000	10.48	42 -76 -14
R. Middle occipital gyrus			0.000	10.06	42 -84 2
L. Precentral gyrus	0.000	21	0.001	9.95	-42 0 54
L. Precentral gyrus	0.000	19	0.003	8.77	-42 4 30
L. Inferior frontal gyrus, opercular part			0.007	8.20	-42 8 18
L. Supplementary motor area	0.000	9	0.007	8.17	-2 0 62
R. Inferior frontal gyrus, opercular part	0.000	6	0.007	8.13	42 12 22
R. Inferior frontal gyrus, triangular part	0.000	5	0.010	7.97	-46 32 14
L. Superior parietal gyrus	0.002	3	0.010	7.93	-26 -64 50
R. Middle occipital gyrus	0.002	3	0.022	7.45	34 -84 26
low frequency vs high frequency (p=0.001; FDRc=36)					
L. Middle occipital gyrus	0.000	666	0.001	9.74	-30 -60 -6
L. Fusiform gyrus			0.011	7.91	-18 -100 2
L. Inferior occipital gyrus			0.028	7.29	-42 -80 6
R. Middle occipital gyrus	0.000	542	0.006	8.30	22 -96 6
R. Fusiform gyrus			0.007	8.15	26 -72 -6
R. Inferior occipital gyrus			0.040	7.09	42 -48 -14
L. Thalamus	0.001	67	0.107	6.50	-14 -20 6
L. Insula	0.000	137	0.142	6.34	-34 24 10
L. Inferior frontal gyrus, triangular part			0.418	5.56	-38 8 -18

The involvement of additional brain regions (the left thalamus, the left insula, the right cingulate gyrus) in the retrieval of low frequency nouns can also be explained on the basis of

previous research showing that the left thalamus and insula are involved in the phonological and semantic aspects of word processing. Several neuropsychological and neuroimaging studies have shown that lesions in the left thalamus result in difficulties in retrieval of words from semantic memory (Mori et al. 1986; Segal et al, 2006), and the atrophy of the left insula grey matter leads to word-finding failures and increased phonological retrieval deficits, or tip-of-the-tongue states (Shafto et al., 2007).

The functional role of the right cingulate cortex is shaped by its connections with the left frontal cortex (Chang et al., 2007). The cingulate cortex takes part in the initialization and execution of the word retrieval process (Chang et al., 2007; Crosson et al., 1999), so the activation of the cingulate cortex in picture naming may reflect the proportion of controlled vs. automatic processing. An additional assumption that the retrieval of low frequency nouns requires more cognitive control than that for high frequency nouns would also explain the finding of greater activation in the cingulate cortex for low frequency vs. high frequency words.

Conclusion

As mentioned, the results of the only previous study on brain correlates of the word frequency effect in Russian (Malutina et al., 2012) differ from those obtained in previous research in English. This discrepancy can be explained in terms of either cross-linguistic differences (Russian vs. English) or in terms of task specificity (the verb-retrieval task used in the Russian-language study vs. the noun-retrieval object naming tasks used in the English-language studies (Graves et al., 2007; Fiebach et al., 2002; Keller et al., 2001).

Data from our fMRI study of the word frequency effect in object naming in Russian are consistent with the previous fMRI studies in English, suggesting that the inconsistency in the earlier literature is due to task rather than language differences. The present results also indicate the possible role of parts of speech and possible interactions of task and word frequency in the brain mechanisms for word retrieval.

References

- DeLeon J., Gottesman R., Kleinman J., Newhart M., Cameron D., Heidler G.J., Lee A., Hillis A.E. (2007) Neural regions essential for distinct cognitive processes underlying picture naming // *Brain*, 130, 1408-1422.
- Khushu S., Kumaran S.S., Tripathi R.P., Gupta A., Jain P.C., Jain V. (2001) Functional magnetic resonance imaging of the primary motor cortex in humans: response to increased functional demands // *J. Biosci.*, Vol. 26, No. 2, 205–215.
- Murtha S., Chertkow H., Beauregard M., Evans A. (1999) The neural substrate of picture

- naming // *J. Cogn Neurosci*, 11(4):399-423.
- Chang Chiung-Chih, Lee Yu Chang, Lui Chun-Chung, Lai Shung-Lon (2007) Right Anterior Cingulate Cortex Infarction and Transient Speech Aspontaneity // *Arch Neurol*. 64(3), 442-446.
- Chee C.Y., Tsai J.L., Yeh T.C., Wu Y.T., Ho L.T., Hung D.L./, Tzeng O.J., Hsieh J.C. (2004) Neuronal correlates of consistency and frequency effects on Chinese character naming: an event-related fMRI study // *Neuroimage*, 23 (4), 1235-45
- Chee M.W., Venkatraman V., Westphal C., Siong S.C. (2003) Comparison of block and event-related fMRI designs in evaluating the word-frequency effect // *Human Brain Mapping*,18(3),186-93.
- Crosson B., Sadek J.R., Bobholz J.A., Gokcay D., Mohr C.M., Leonard C.M., Maron L., Auerbach E.J., Browd S.R., Freeman A.J., Briggs R.W. (1999) Activity in the Paracingulate and Cingulate Sulci during Word Generation: An fMRI Study of Functional Anatomy// *Cerebral Cortex*, jun. 9, pp. 307-316.
- Fiebach C.J., Friederici A.D., Muller K., von Cramon D.Y. (2002) fMRI evidence for dual routes to the mental lexicon in visual word recognition // *J. Cogn. Neurosci*. 14, 11 –23.
- Graves W.W., Grabowski T.J., Mehta S. (2007) A neural signature of phonological access: distinguishing the effects of word frequency from familiarity and length in overt picture naming // *J Cog Neurosci*.,19(4), 617-31.
- Ho-Ling Liu, Wan-Ting Liao, Shin-Yi Fang, Tieh-Chi Chu, Li Hai Tan (2004) Correlation between temporal response of fMRI and fast reaction time in a language task *Magnetic Resonance Imaging*, Volume 22, Issue 4, 451–455.
- Keller T.A., Carpenter P.A. (2001) The neural bases of sentence Comprehension: a fMRI examination of syntactic and lexical processing // *Cerebral Cortex*, V, 11, 223-237.
- Lyashevskaya O.N., Sharov S.A. (2009) Frequency dictionary of the modern Russian language (the Russian National Corpus) // M.: Azbukovnik (in Russian).
- Malutina S.A., Dragoy O.V., Petrushevskiy A.G., Fedina O.N., Ivanova M.V., Sevan D.A., Gutyrchik E.F. Neurophysiological correlates of word frequency during naming task. // *International Symposium on Functional Neuroimaging: Basic Research and Clinical Applications*. URL: http://psyjournals.ru/neuroimag_2012/issue/53741.shtml
- Meschyan G., Hernandez A., (2002) Age of acquisition and word frequency:Determinants of object-naming speed and accuracy // *Memory & Cognition*, 30 (2), 262-269.
- Mori, E., Yamadori, A. and Mitani, Y. (1986), Left thalamic infarction and disturbance of verbal memory: A clinicoanatomical study with a new method of computed tomographic stereotaxic lesion localization. *Ann Neurol.*, 20, 671–676.

- Oberg G., Ramirez M. (2006) Cross-linguistic meta-analysis of phonological fluency: Normal performance across culture // *International Journal of Psychology*, vol. 41, issue 5, 2006.
- Segal J.B., Williams R., Kraut M. A., Hart J. (2003) Semantic memory deficit with a left thalamic infarct *Neurology* 22, 2003, vol. 61, № 2, 252-254.
- Shafto M.A., Burke D.M., Stamatakis E.A., Tam P.P., Tyler L.K. (2007) On the Tip-of-the-Tongue: Neural Correlates of Increased Word-finding Failures in Normal Aging // *Journal of cognitive neuroscience*, Vol.19, № 12, 2060-2070.

Roza M. Vlasova

National Research University Higher School of Economics (Moscow, Russia), Faculty of Philology, Laboratory of Neurolinguistics.

E-mail: rvasova@hse.ru, Tel. +7 (916) 487-47-61

Ekaterina V. Pechenkova

Institute of Practical Psychology and Psychoanalysis (Moscow, Russia)

E-mail: evpech@gmail.com

Valentin E. Sinitsyn

Federal Center of Medicine and Rehabilitation

E-mail: vsini@mail.ru

Any opinions or claims contained in this Working Paper do not necessarily reflect the views of HSE.

© Vlasova, 2013