

OBJECT AND ACTION NAMING IN PATIENTS BEFORE AND AFTER GLIOMA RESECTION

Chrabaszcz A.¹, Buklina S.², Tolkacheva V.¹, Poddubskaya A.², Dragoy O.¹

1. Neurolinguistics Laboratory, Higher School of Economics, Moscow, Russia, 2. Scientific Research Neurosurgery Institute of N. N. Burdenko



1. BACKGROUND

- Frontal and temporal brain areas in the LH are classically associated with language processing [2,9,13].
- Damage to these areas causes sustained and distinct linguistic deficits in stroke patients [6], but not necessarily in tumor patients [1].
- Neuroimaging studies with healthy adults and lesion studies with aphasia patients show that objects and actions are represented in at least partly distinct neural substrates, suggesting a differential brain organization for nouns and verbs (nouns are subserved by temporal areas; verbs - frontal areas) [4,5,7,10,11,12].

2. RESEARCH QUESTIONS

1. Are objects and actions distinctly processed in temporal and frontal brain regions, respectively, by patients with brain tumor?
2. Do reorganization capacities (due to neuroplasticity) of frontal and temporal areas differ for object and action processing?

3. PATIENTS

N=14 patients (native Russian, right-handed) with tumor in the temporal (n=7) and frontal (n=7) lobe.

- dysembryoplastic neuroepithelial tumor: 1
- diffuse astrocytoma (WHO II): 1
- diffuse oligoastrocytoma (WHO II): 4
- anaplastic astrocytoma (WHO III): 1
- anaplastic oligoastrocytoma (WHO III): 4
- glioblastoma (WHO IV): 3

REFERENCES

1. Anderson, S. W., et al. (1990). Neuropsychological impairments associated with lesions caused by tumor or stroke. *Archives of neurology*, 47(4), 397-405.
2. Berker, E. A., Berker, A. H., & Smith, A. (1986). Translation of Broca's 1865 report: localization of speech in the third left frontal convolution. *Archives of Neurology*, 43(10), 1065-1072.
3. Chang, E. F., et al. (2015). Contemporary model of language organization: an overview for neurosurgeons. *Journal of neurosurgery*, 122(2), 250-261.
4. Chen, S., Bates, E. (1998). The dissociation between nouns and verbs in Broca's and Wernicke's aphasics: Evidence from Chinese. *Special issue on Chinese aphasia, Aphasiology*, 12(1), 5-36.
5. Damasio, A. R., Tranel, D. (1993). Nouns and verbs are retrieved with differently distributed neural systems. *PNAS*, 90(11), 4957-4960.
6. Goodglass, H. (1993). *Understanding aphasia*. Academic Press.
7. Mestres-Misó, A., et al. (2010). Neural differences in the mapping of verb and noun concepts onto novel words. *NeuroImage*, 49(3), 2826-2835.
8. Ojemann, G., et al. (1989). Cortical language localization in left, dominant hemisphere: an electrical stimulation mapping investigation in 117 patients. *Journal of neurosurgery*, 71(3), 316-326.
9. Poeppel, D., & Hickok, G. (2004). Towards a new functional anatomy of language. *Cognition*, 92(1), 1-12.
10. Rapp, B., Caramazza, A. (2002). Selective difficulties with spoken nouns and written verbs: A single case study. *Journal of Neurolinguistics*, 15, 373-402.
11. Shapiro, K., et al. (2001). Grammatical distinctions in the left frontal cortex. *Journal of Cognitive Neuroscience*, 13(6), 713-720.
12. Shapiro, K., Caramazza, A. (2003). Grammatical processing of nouns and verbs in left frontal cortex? *Neuropsychologia*, 41, 1189-1198.
13. Wernicke, W., & Kohlenbach, H. W. (1977). Versuche zur kultur isolierter mikrosprosen von Nicotiana und Hyoscyamus. *Zeitschrift für Pflanzenphysiologie*, 81(4), 339-340.

For questions, contact achrabaszcz@hse.ru

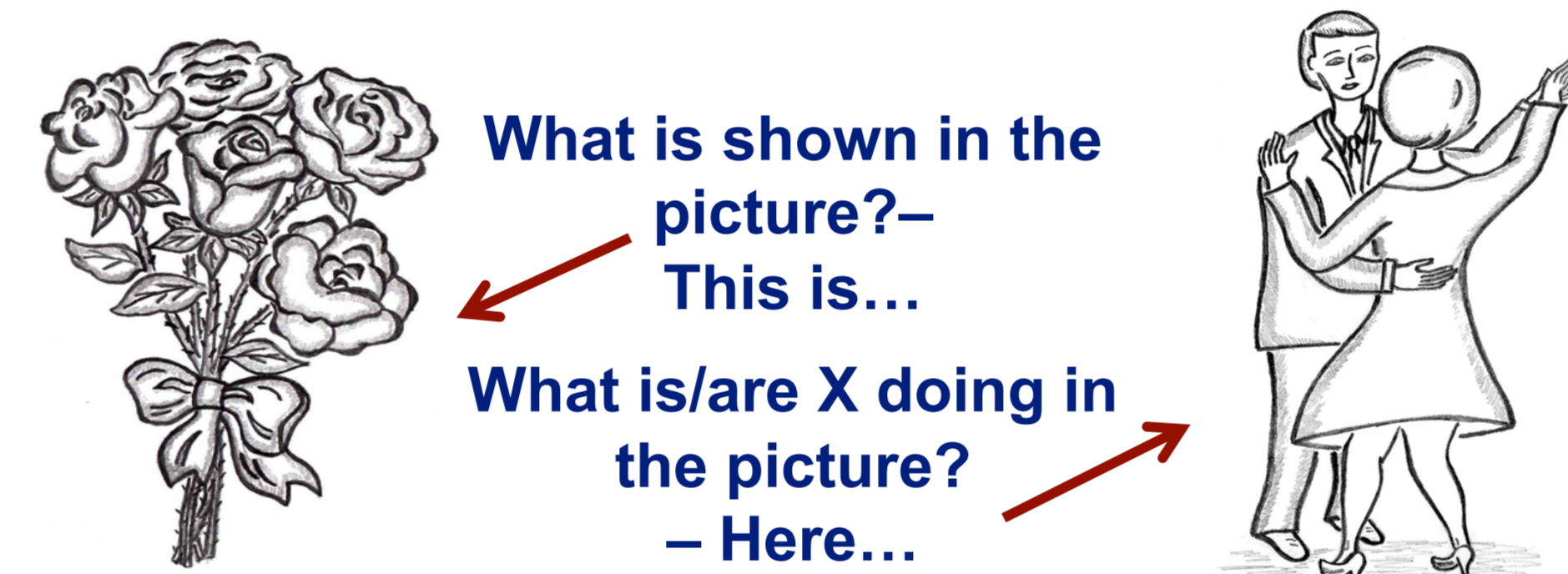
4. METHOD AND MATERIALS

Russian Object and Action Naming Test

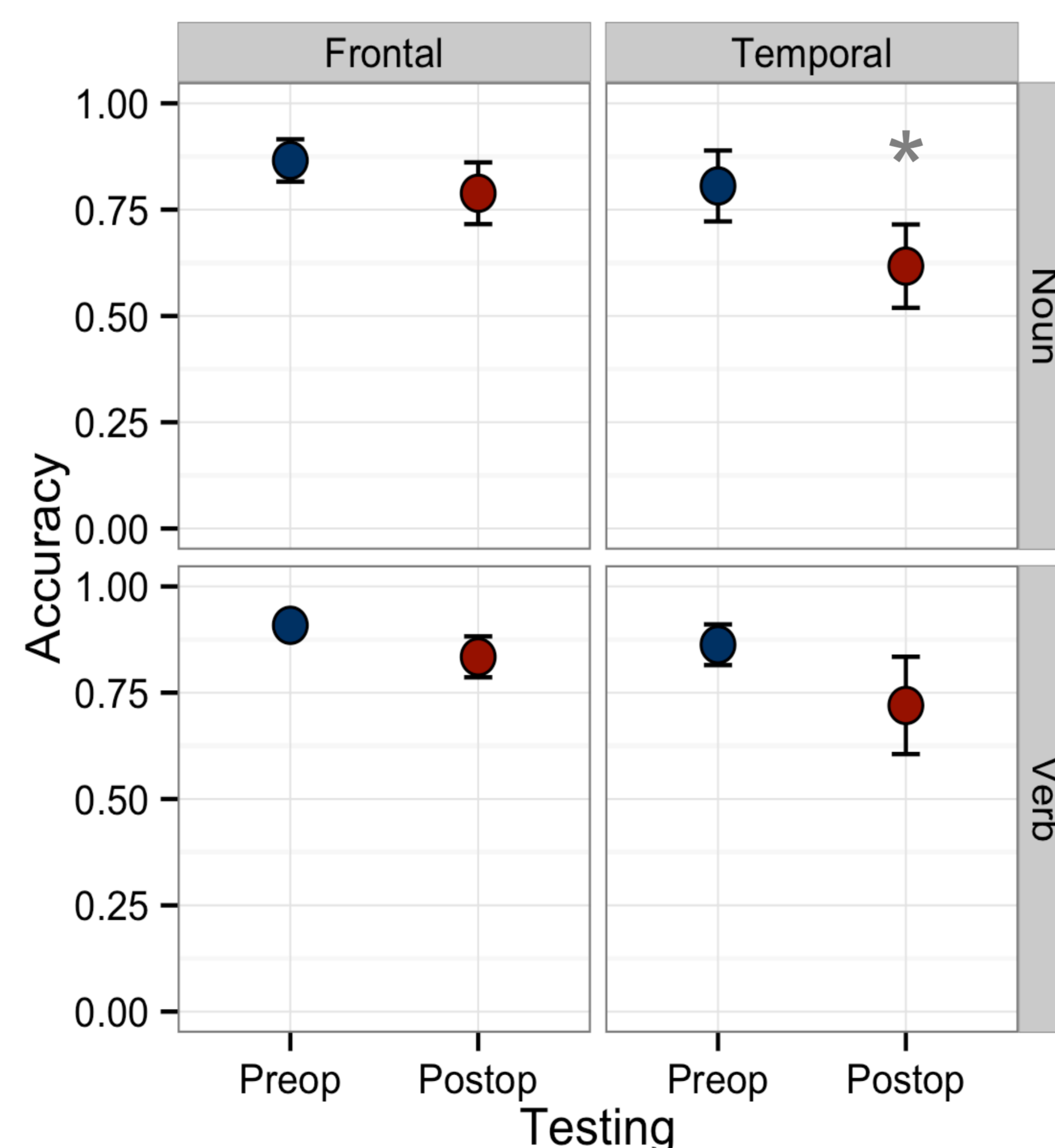
(administered pre-, intra-, post-operatively)

- routinely used in DES language mapping [8];
- appropriate for tumor patients because word-finding difficulties are the most common linguistic symptoms;
- involves various cognitive sub-processes (object recognition, memory recall, lexical retrieval, phonological encoding, etc.) [3]

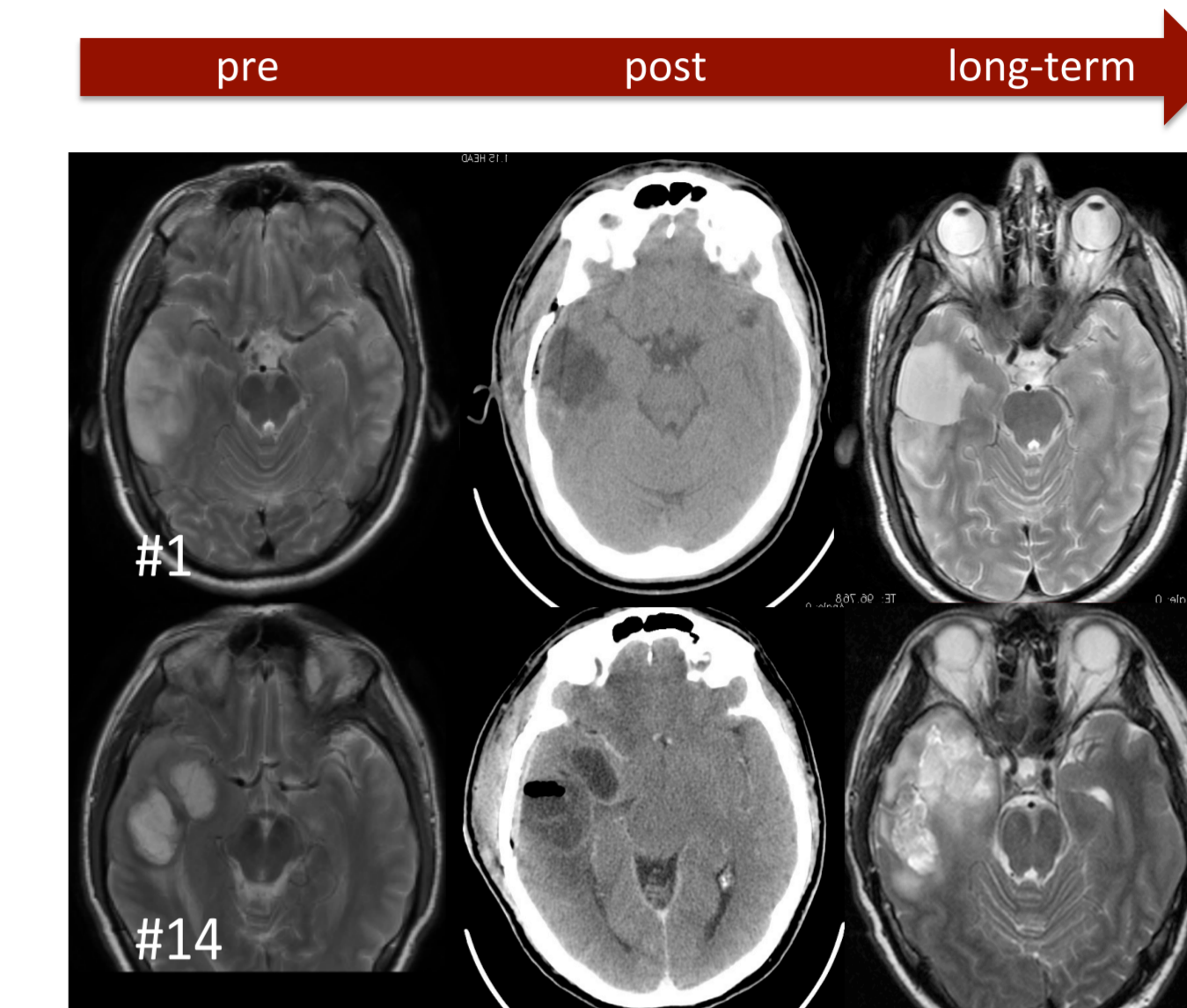
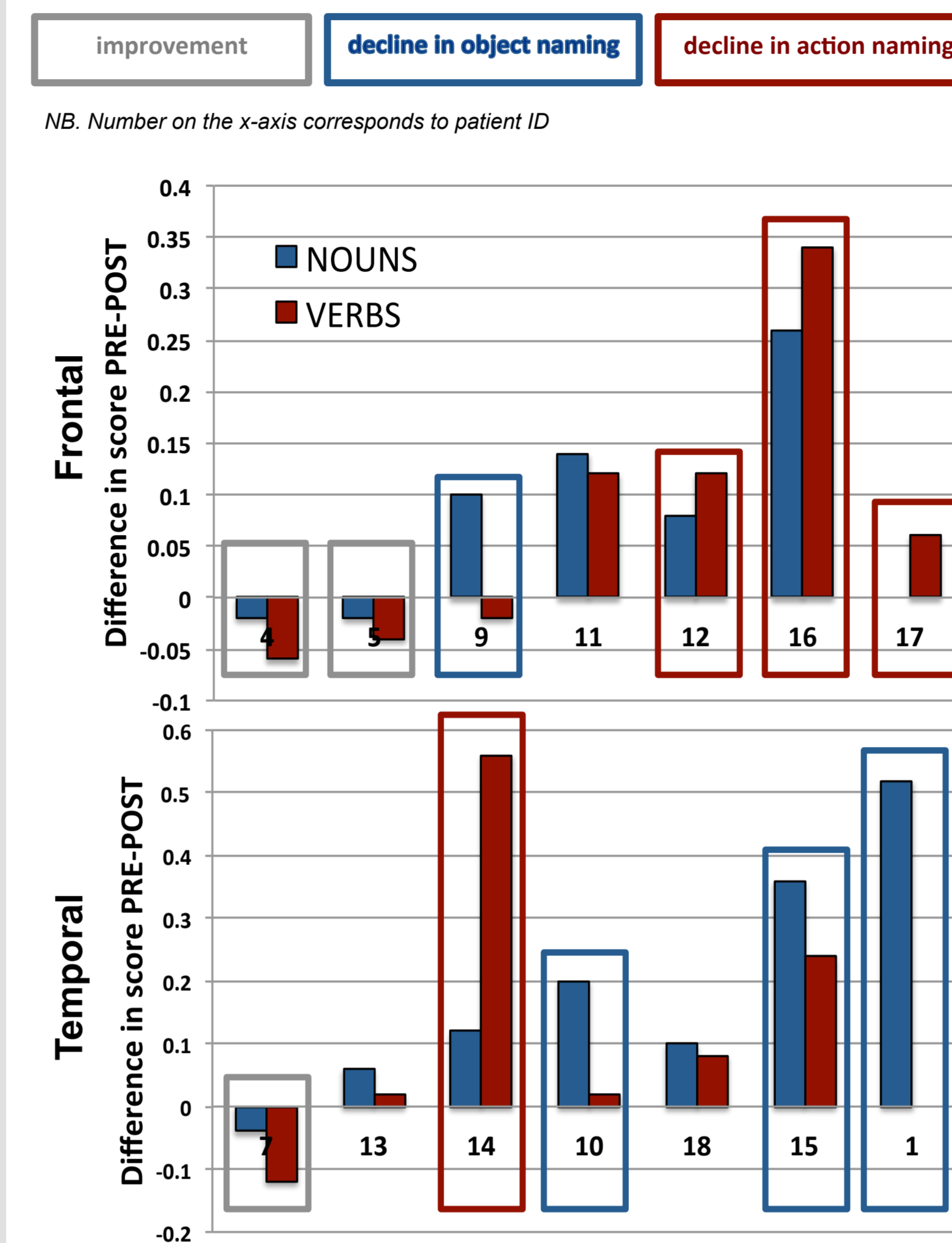
Design: 50 object & 50 action b/w pictures; controlled for psycholinguistic parameters; display interval= 3s



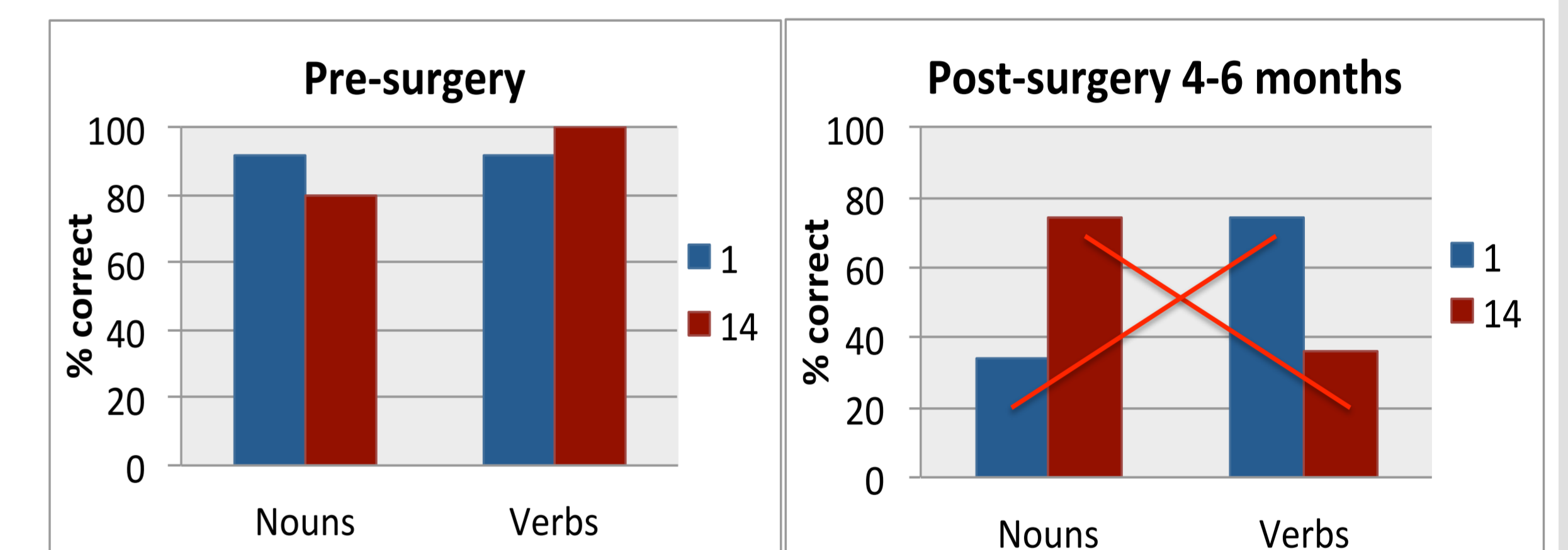
5a. RESULTS: OVERALL MEAN ACCURACY



5b. RESULTS: INTERPATIENT VARIABILITY



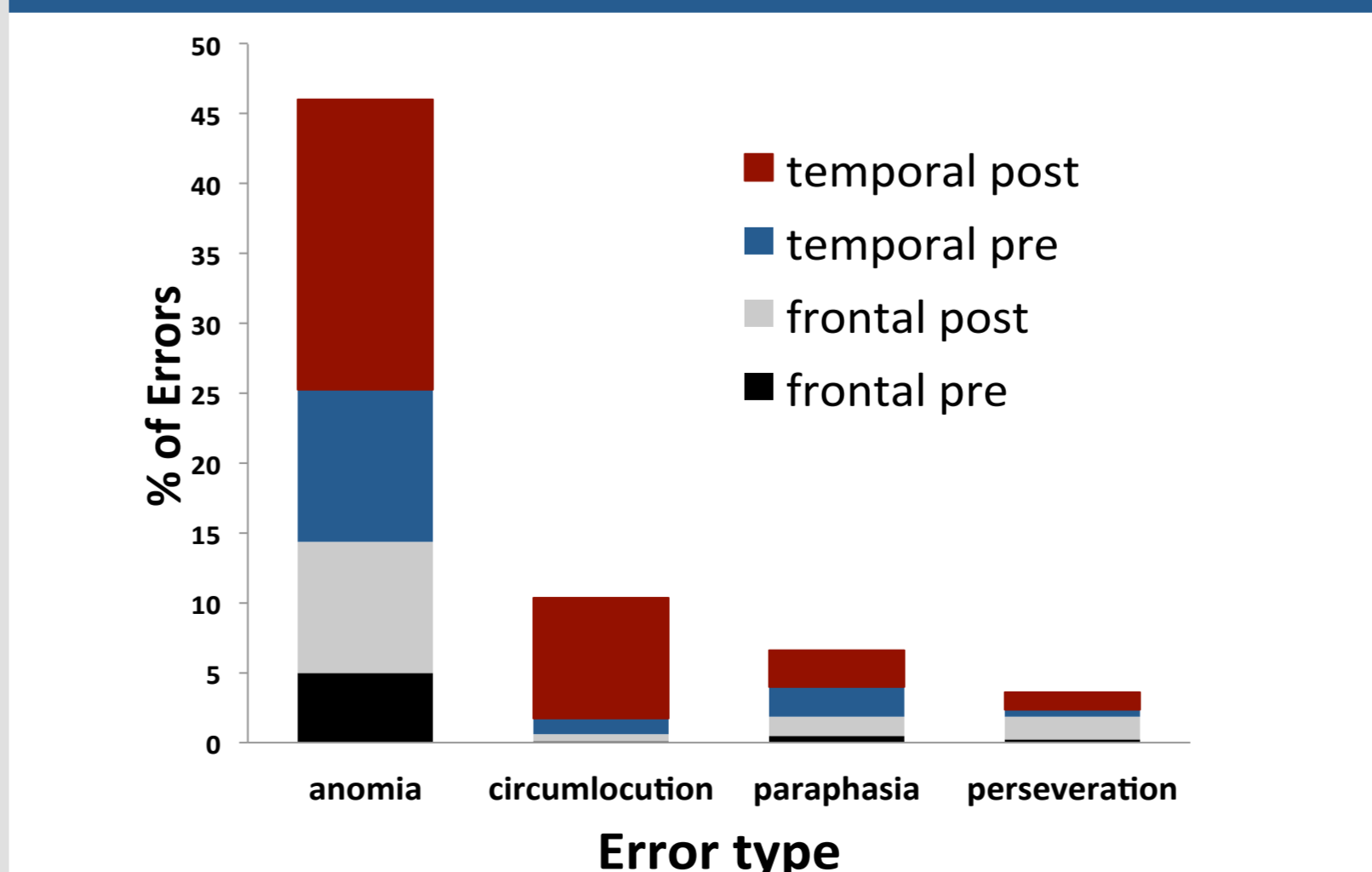
	ID #1	ID #14
Age	46	55
Gender	male	male
Tumor type	oligoastrocytoma	glioblastoma
WHO grade	2	4
Time since surgery	~6 mon.	~4 mon.
Localization	STG, MTG, ITG	STG, MTG, ITG, insula, putamen



5c. RESULTS: COVARIATES

Effect	Estimate	SE	z value	p value
Familiarity	0.43	0.09	4.6	< 0.001
AoA	-1.11	0.14	-8	< 0.001
Word-to-image corr	-0.4	0.1	-4.1	< 0.001
Log freq	0.9	0.11	7.78	< 0.001
Syll. length	-0.17	0.07	-2.4	< 0.05

5d. RESULTS: ERROR TYPE



6. SUMMARY

- The mere fact of glioma in the eloquent cortices—IFG and STG—does not cause a significant deterioration of object or action naming in either frontal or temporal patient groups → **effect of neuroplasticity**;
- Post-op mean accuracy rate differs in the two groups of patients: 'frontal' patients do not show a sig. accuracy drop for either action or object naming, 'temporal' patients perform worse on both nouns (a sig. drop of 26%) and verbs (a drop of 19%) → **linguistic functions that are grounded in the temporal lobe are less reluctant to reorganization than those based in the frontal areas**;
- **But**, much inter-group and inter-patient variability is observed (3 people showed improvement, 4 – decline in action naming; 4 – decline in noun naming; 3 – no sig. difference b/n object and action naming) → **tumor location and its resection does not unambiguously predict post-op recovery pattern for naming function** (e.g., 'temporal' patients #1 and #14 demonstrate a directly opposite pattern);

* The present test is the first naming test normed and adapted for the Russian language that is used intra-operatively during awake craniotomy.